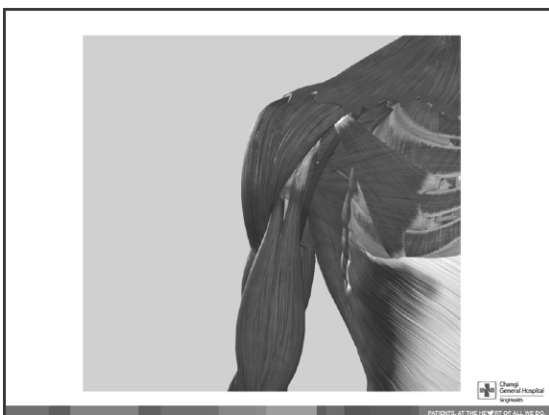
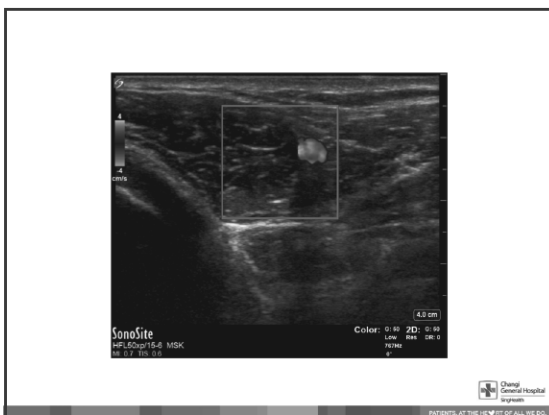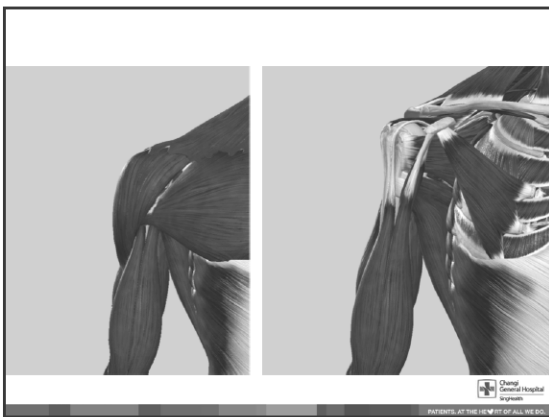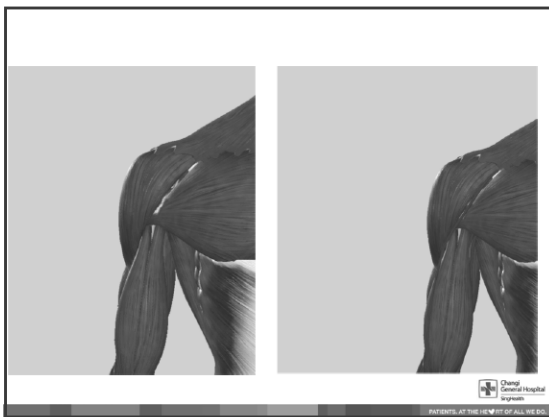
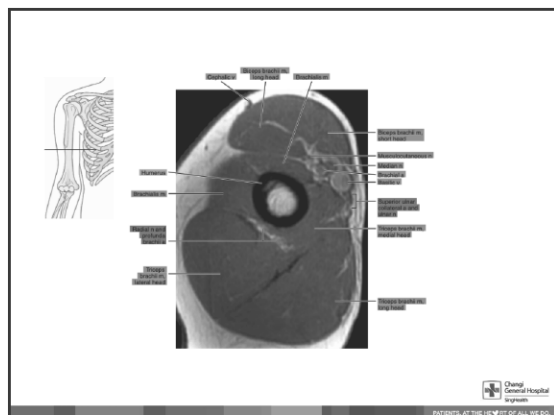
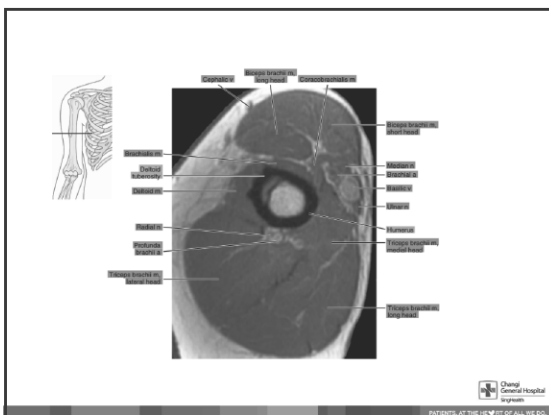
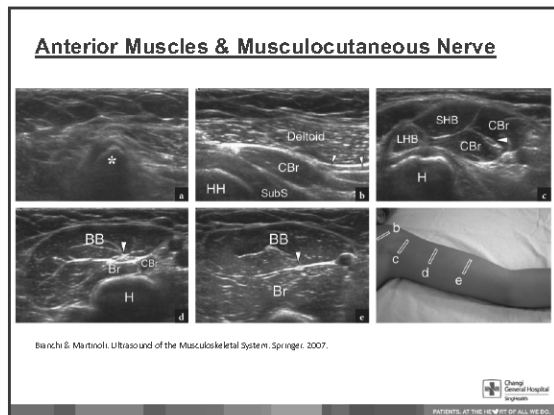
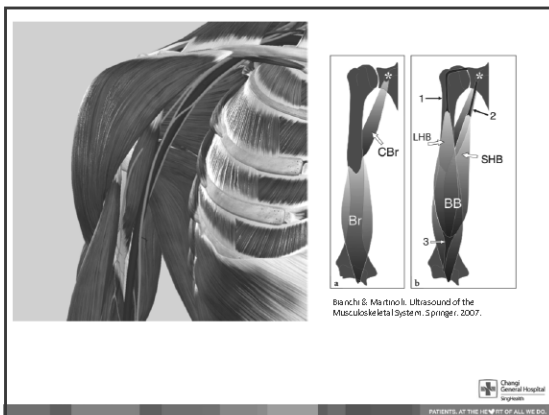
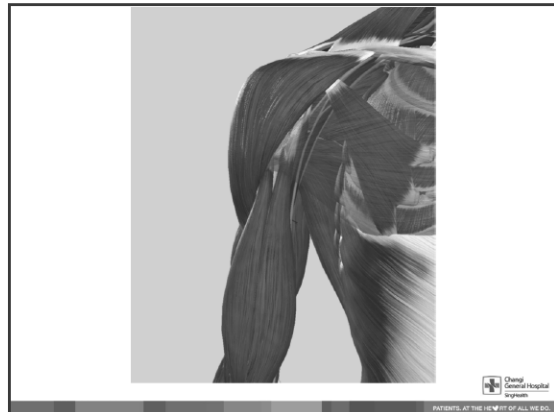
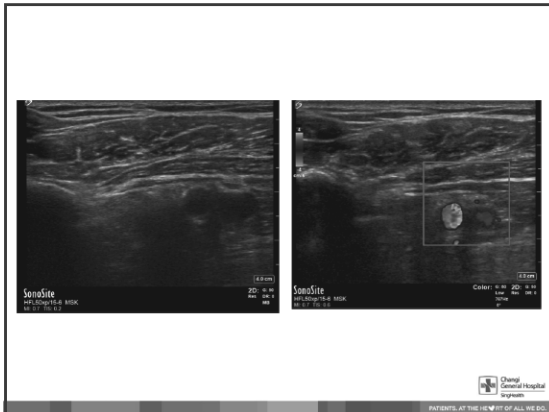


Outline for Arm and Elbow Ultrasound

- Anatomy
- Muscle localization for spasticity management
 - Biceps brachii
 - Brachialis
- Indications for elbow ultrasound
- Scan “protocol” for elbow





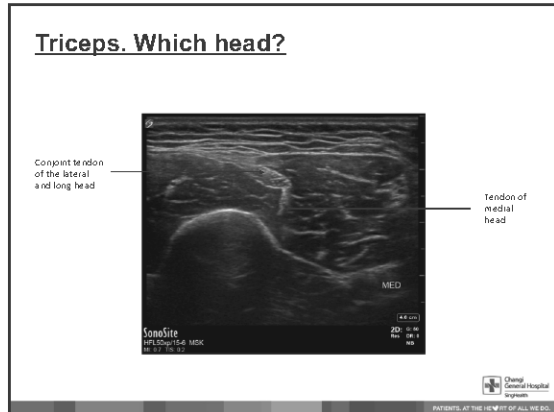
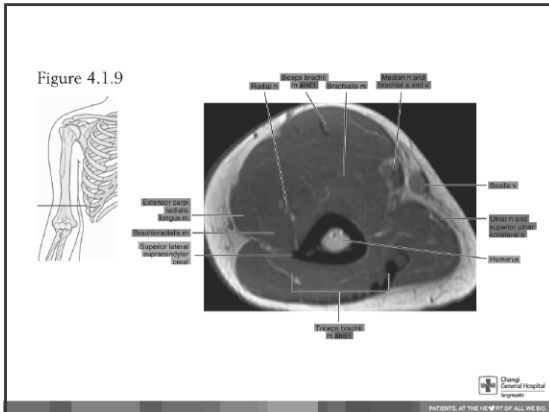
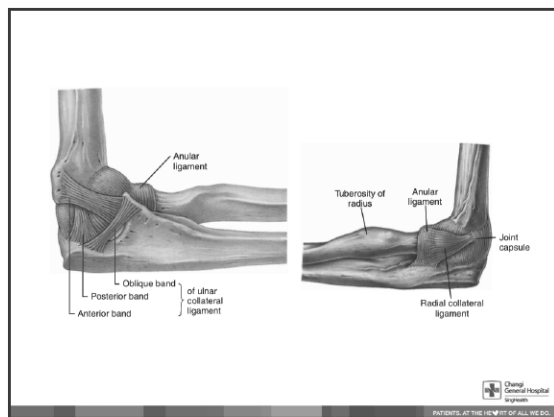
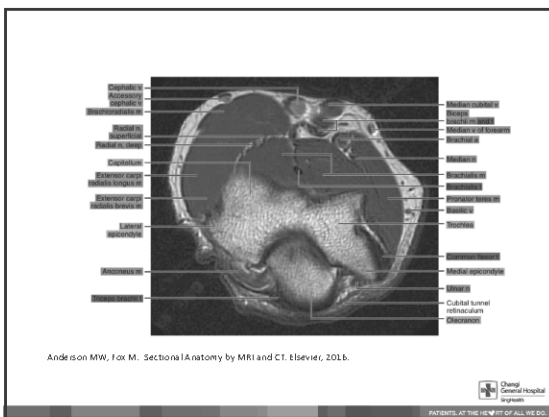
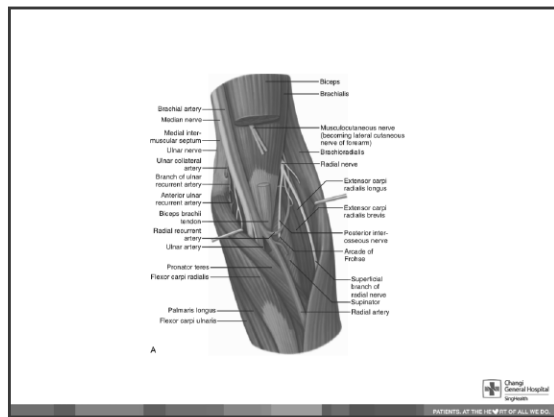


Table 2 Elbow- Distal results for evidence levels and final consensus, a comparison between 2012 and 2017

Clinical question	Evidence level 2012	Final consensus 2012	Evidence level 2017	Final consensus 2017
Tendon and soft tissues				
Lateral epicondylitis	A	3	Unchanged	Unchanged
Lateral collateral ligament	D	6	C	2
Medial collateral ligament	No	3	Unchanged	Unchanged
Medial collateral ligament	C	2	B	Unchanged
Brachy tendon complex	No	2	Unchanged	Unchanged
Brachioradialis bursitis	No	2	Unchanged	Unchanged
Spuritis	B	2	Unchanged	Unchanged
Sigale's calcific effusion	B	3	Unchanged	Unchanged
Ticeps tendon injury	C	3	Unchanged	Unchanged
Swinging elbow injury	C	3	Unchanged	Unchanged
Olecranon bursitis	D	3	Unchanged	Unchanged
Bones				
Loose bodies	C	1	Unchanged	Unchanged
Lateral condyle fracture in children/teenagers	D	6 to 3	Unchanged	2
Radial head subchondral fracture	D	1	Unchanged	Unchanged
Scavenger fracture	C	2	B	Unchanged
Separation or other fracture: posterolateral/posterior	B	6	Unchanged	Unchanged
Olecranon fracture	No	1	Unchanged	Unchanged
Nerves				
Radial nerve compression	No	3	Unchanged	Unchanged
Median nerve compression: pronator syndrome	No	3	Unchanged	Unchanged
Chair nerve neuropathy	B	3	C	Unchanged
Ulnar nerve entrapment	D	3	C	Unchanged

Grade 0 - no indication; grade 1 - of other imaging technique was not appropriate; grade 2 - equivalent to other imaging techniques; other technique might provide additional information; grade 3 - the ability to identify other techniques early provides more information

Chang General Hospital System
PATIENTS AT THE HEART OF ALL WE DO.



Lateral Elbow

St. Camer... of the lateral elbow ligaments... [PMJ Orthop Surg 2019; 5\(1\): 453-470](#)

Chang General Hospital
PATIENTS AT THE HEART OF ALL WE DO.

Medial Elbow

Martins, 2008 - Posterior Elbow... [J Prosthet Dent 2010; 103\(4\): 249-254](#)

Chang General Hospital
PATIENTS AT THE HEART OF ALL WE DO.

US Elbow Checklist

Anterior
Bachialis
Biceps brachii tendon
Median nerve
Anterior joint recess

Lateral
Common extensor tendon
Radial collateral ligament/lat UCL
Radial head and annular ligament
Capitellum
Radial nerve

Medial
Ulnar collateral ligament
Common flexor tendon
Ulnar nerve

Posterior
Posterior joint recess
Triceps tendon
Olecranon bursa

Chang General Hospital
PATIENTS AT THE HEART OF ALL WE DO.

Anterior

Tagliafico AS et al. Elbow ultrasound: Anatomy, variants, scanning technique. *Radiology*. June 2016; 279(3): 558-550

Chang General Hospital
PATIENTS AT THE HEART OF ALL WE DO.

Chang General Hospital
PATIENTS AT THE HEART OF ALL WE DO.

Biceps Tendon

Tagliafico AS et al. Elbow ultrasound: Anatomy, variants, scanning technique. *Radiology*. June 2016; 279(3): 558-550

Chang General Hospital
PATIENTS AT THE HEART OF ALL WE DO.

Lateral

Tagliafico AS et al. Elbow ultrasound: Anatomy, variants, scanning technique. Radiology. June 2018;273(1):838-850

Chang General Hospital System
PATIENTS. AT THE HEART OF ALL WE DO.

Posterior Interosseous Nerve

ESSR Musculoskeletal Ultrasound Technical Guidelines II: Elbow

Chang General Hospital System
PATIENTS. AT THE HEART OF ALL WE DO.

Posterior

ESSR Musculoskeletal Ultrasound Technical Guidelines II: Elbow

Chang General Hospital System
PATIENTS. AT THE HEART OF ALL WE DO.

Posterior

Tagliafico AS et al. Elbow ultrasound: Anatomy, variants, scanning technique. Radiology. June 2018;273(1):838-850

ESSR Musculoskeletal Ultrasound Technical Guidelines II: Elbow

Chang General Hospital System
PATIENTS. AT THE HEART OF ALL WE DO.

Chang General Hospital System
PATIENTS. AT THE HEART OF ALL WE DO.

Medial

ESSR Musculoskeletal Ultrasound Technical Guidelines II: Elbow

Chang General Hospital System
PATIENTS. AT THE HEART OF ALL WE DO.

Other approaches to study the biceps tendon

Medial

Copyright © 2014 Elsevier. All rights reserved. For more information on this journal please go to the journal web site at www.elsevier.com

Chang Gung Memorial Hospital
PATIENTS. AT THE HEART OF ALL WE DO.

Other approaches to study the biceps tendon

Lateral

Copyright © 2014 Elsevier. All rights reserved. For more information on this journal please go to the journal web site at www.elsevier.com

Chang Gung Memorial Hospital
PATIENTS. AT THE HEART OF ALL WE DO.

Other approaches to study the biceps tendon

Posterior

Copyright © 2014 Elsevier. All rights reserved. For more information on this journal please go to the journal web site at www.elsevier.com

Chang Gung Memorial Hospital
PATIENTS. AT THE HEART OF ALL WE DO.

Recommended Readings & References

ESSENTIAL ANATOMY 5

Chang Gung Memorial Hospital
PATIENTS. AT THE HEART OF ALL WE DO.